Semi-rigid Ureteroscopy

Complications and How to avoid?

Prof. Dr. Abdelbasset Badawy

Dept. of Urology, Sohag University Hospital

Introduction

- The first documented ureteroscopy was in 1912 when Hugh Hampton Young advanced a pediatric cystoscope into the dilated ureter of a child with posterior urethral valves.
- Ureteroscopy for upper tract urolithiasis disease started in 1980s.
- Advances in the design of ureteroscopes and their accessory instruments make modern ureteroscopy quite safe.

Introduction

- However, complications of ureteroscopy still do occur and can result in severe ureteral injury and possible kidney loss.
- Understanding of the different possible complications and predisposing risk factors can help to anticipate and avoid these complications.
- Appropriate and timely management of complications is a crucial step to safe and successful ureteroscopy.

Indications for URS

- The indications for ureteroscopy fall into two categories, diagnostic and therapeutic.
- Diagnostic indications include evaluating a patient with a radiological filling defect, haematuria, or positive cytology of the upper tract, or surveillance of patients with upper tract malignancies that have been treated endoscopically.
- Therapeutic indications include removing upper tract stones or other foreign bodies, treating upper tract malignancies, or treating strictures or areas of obstruction.

Classification of URS Related Complications

Major

Significant further surgical or medical therapy is required or if the complication is life-threatening

Minor

Non-operative management or minimal intervention will be corrective.

Intraoperative Complications

- **Minor Complications:**
  - Failure to access the upper tract
  - Bleeding
  - Thermal damage
  - Instrument malfunction
  - Mucosal abrasion
  - False passage
  - Extraversion
  - Ureteral perforation

Intraoperative Complications

- **Major Complications**
  - Intussussception
  - Avlusion
  - perforation

Failure to access the upper tract

Why access to ureter is challenging?

- Narrow intramural ureter
- Ureteral injury e.g. perforation, mucosal flab
- External ureteral compression

Figure 27-14 *A*, Guidewire placed into upper collecting system. *B*, Balloon inflated at level of ureteral orifice and intramural tunnel. *C*, Balloon deflated, advanced farther up the ureter and reinflated.

Failure to access the upper tract

Why access to ureter is challenging?

- Ureteral strictures
- Severe spinal column angulation
- Renal and ureteral ectopia
- Prior ureteral reimplantation
- Ureterocele
- BPH

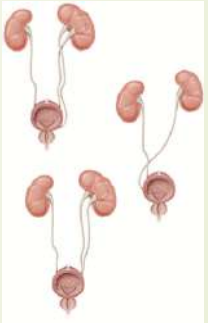

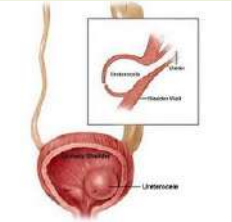

Failure to access the upper tract
How to avoid?

- When access problems are encountered, the safest option is to place a ureteral stent and allow for passive ureteral dilation over 1–2 weeks; repeat ureteroscopy thereafter.
- the motion of the guidewire should be monitored all throughout the procedure under direct control
- The previously inserted hydrophilic guidewire may then be exchanged with an Amplatz super stiff guidewire

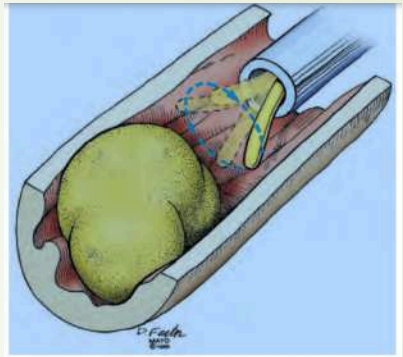

Figure 27-17 A small caliber ureteroscope just inside the intramural tunnel and attempted passage of a guidewire beyond an impacted stone.

Failure to access the upper tract
How to avoid?

- When access to the upper urinary tract is still not possible despite passive ureteral dilation with a stent, a percutaneous antegrade approach may be considered.

- An alternative is flexible URS to facilitates safe, reliable access to the mid- and upper ureter and collecting system.

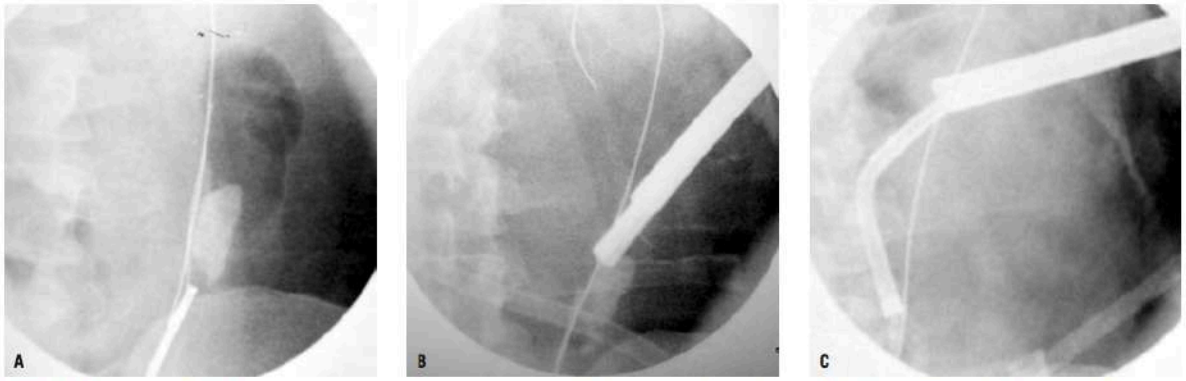

Figure 30-1 *A*, Large complex proximal stone, initial ureteroscopic retrograde manipulation by passing a guidewire into the collecting system. *B*, Antegrade percutaneous approach complete stone fragmentation. *C*, Flexible antegrade ureteroscopy allows complete evaluation and residual stone removal.

Bleeding

- Bleeding during ureteroscopy is rarely of significant concern
- Most often bleeding is encountered with ureteral orifice dilation, mucosal, or calyceal injury from wire or ureteroscope trauma, or during stone lasing and manipulation.
- The incidence of bleeding severe enough to cause premature termination of ureteroscopy has been reported between 0.1 and 2.1% due to injury to a crossing vessel during endopyelotomy or endoureterotomy.
- Minor bleeding can be minimized with careful technique and usually resolves with termination of the procedure.

Bleeding

- More severe bleeding requires termination of the procedure and placement of a ureteral stent to aid in drainage and to prevent clot colic.
- Prolonged bleeding should be closely observed but will usually resolve without further intervention.
- If severe bleeding occurs, particularly after endoureterotomy or endopyelotomy, placement of a ureteral dilating balloon (24–30 F) will tamponade the bleeding and allow time to stabilize the patient until further intervention, such as arteriography or embolization, can be performed.

Thermal Tissue Damage

- Modern ureteroscopes are well insulated and if maintained properly should not cause ureteral thermal injury.
- Some of the instruments commonly used during uretersocopy, such as lasers and electrohydraulic lithotripters can cause thermal collateral damage to surrounding tissues, with injury ranging from small mucosal defects to large areas of necrosis.
- EHL in particular is associated with a significant temperature increase and has the greatest risk of ureteral injury.

Thermal Tissue Damage How To Avoid?

- Avoid direct contact with the mucosa and keep the lithotripsy probe or laser fiber directed parallel rather than perpendicular to the ureteral wall to avoid stray energy from contacting the wall.
- Because the Nd:YAG laser penetrates to a depth of 5 to 6 mm, its use on the ureteral wall should be minimized to avoid damage to adjacent organs.

Thermal Tissue Damage How To Avoid?

- Thermal injury can usually be managed with observation or stenting, although delayed stricture remains a possible late sequelae.
- Four to six weeks after ureteral stent removal, renal ultrasound can be used as a screen for ureteral stricture formation, as this has been reported after thermal injuries.

Instrument Malfunction

- Successful ureteroscopy depends on the proper function of multiple instruments including endoscope, light source, lithotripsy device, stone basket, biopsy forceps, and digital camera.
- Any of these may be damaged during surgical use or during processing and sterilization.
- Even with the most fastidious preventative efforts, equipment breakdowns will occur. In this event, broken items should be removed from the field, and the procedure should be stopped if necessary, because continuing with faulty equipment may escalate a minor annoyance into a major complication.

Instrument Malfunction

- Breakage of basket occurs due to thermal effect of laser fiber causing ureteral lacerations when being removed.

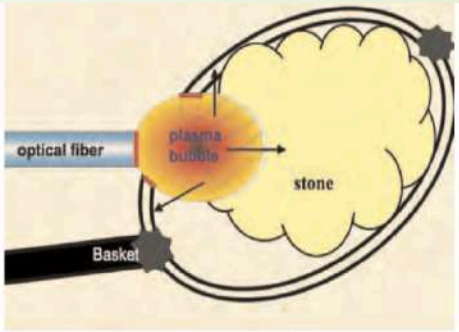

Figure 36-14 Schematic representation: at the tip of the Holmium laser fiber, plasma bubble is formed; that destroys both the stone and, eventually, the basket wires.

- Carry on with laser lithotripsy.
- Remove the basket under vision with a grasper tweezers to keep the broken coils away from the wall of the ureter.

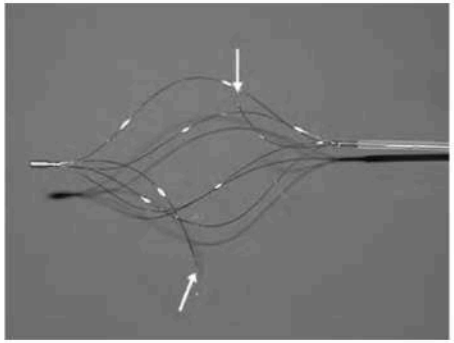

Figure 36-15 One of the basket wires is disrupted after using holmium laser for fragmentation of an entrapped stone.

- An alternative would be to use laser to complete breakage of coils and remove the broken basket in 2 parts.

Instrument Malfunction
How To Avoid?

- ✓ Proper care of instruments during cleaning, sterilization, storage, and use should minimize equipment breakage and down time.
- ✓ Before each use, the ureteroscope should be checked for broken fibers, and the clarity and focus of the optics.
- ✓ It is imperative that the surgeon be well acquainted with the ureteroscope and accessories, including the size of the working channel and the accessories, the mechanism of action of the device, and the working settings of lithotrites.

False Passage

- Occurs when an instrument passes across the ureteral mucosal and tunnels submucosally for some distance, but does not completely perforate through the outer layers of the ureter.
- Incidence is reported between 0.4 and 1%.
- Ureteral strictures, considerable ureteral tortuosity, and impacted ureteral stones all may increase the risk of submucosal tunneling.

False Passage

- Resistance to easy guidewire or instrument advancement is a clue to possible submucosal tunneling.

- Small, short submucosal tunnels infrequently lead to termination of ureteroscopy and can be managed with short-term ureteral stenting.
- Unrecognized submucosal tunneling over a long distance with subsequent dilation or passage of large instruments can lead to devastating ureteral injury.

False Passage
How to avoid?

- ✓ Retrograde ureteropyelograms can help expose submucosal tunnels or confirm intraluminal wire placement.
- ✓ If a wire is detected submucosally, retrogression of the wire followed by intraluminal placement is recommended.
- ✓ This can also be done under direct vision with a ureteroscopy placed just distal to the false passage.
- ✓ Utilizing floppy tipped guidewires, especially when trying to negotiate past ureteral stones, strictures or severe tortuosity.

Extravasation

- Incidence <1% and refers to the migration of intraluminal contents outside of the upper collecting system.
- Mechanism
  - iatrogenic perforation in the collecting system.
  - forniceal rupture.
- Fluids such as urine, irrigant, blood, and contrast as well as solids such as tissue and stone fragments may extravasate.
- Extravasation of small fluid volumes is often insignificant. However, large volume extravasation can have clinically important consequences.
- Urine extravastion can lead to urinoma formation and subsequent mass effect if large, abscess formation if infected, and possibly periureteral fibrosis.

Extravasation
How to avoid?

- ✓ Hypervolemia and hyponatermia can result from the extravasation and absorption of large amounts of hypotonic irrigant, Therefore, as a rule, water should be avoided during ureteroscopy.

- ✓ Limiting high pressure irrigation can help reduce the risk of extravasation

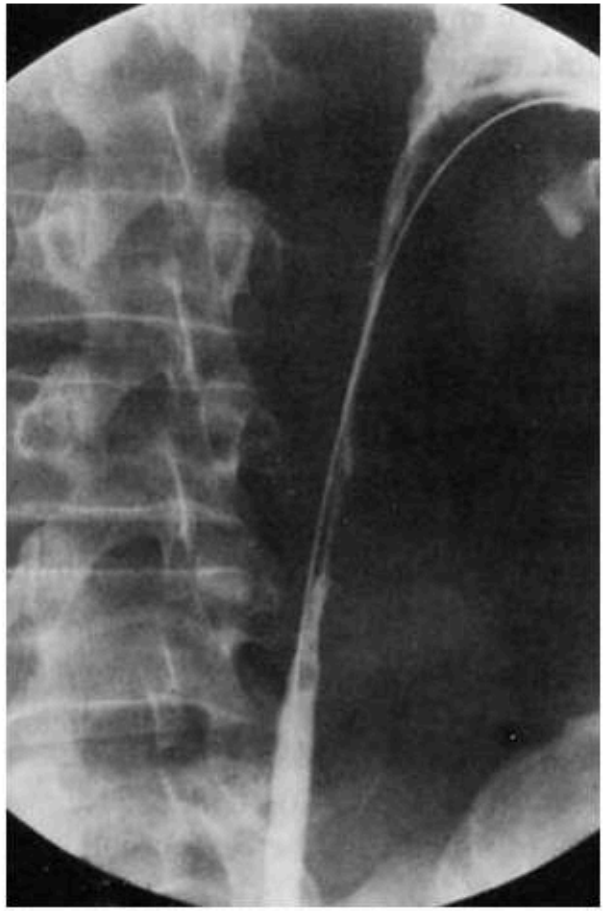

Figure 36-20 A long stricture developed after a ureteroscopic stone extraction in which there was a perforation leading to extensive extravasation.

Stone Extrusion

- Extrusion of non-infected stones or stone fragments into the retroperitoneum usually has no adverse long-term effects and this complication can be managed similar to a ureteral perforation.
- Attempts should not be made to retrieve the stone because this often enlarges the ureteral perforations, increases the associated inflammation, and may increase the long-term stricture risk.
- Documenting stone location with perioperative imaging and informing the patient should help reduce misdiagnosis and unnecessary future procedure.

Ureteral Perforation

- Ureteral perforation occurs when a hole is created across all layers of the ureteral wall.
- Larger stones or impacted stones, retroperitoneal fibrosis, and prolonged operative time all increase the risk of ureteral perforation.
- Small ureteral perforations, such as small puncture holes from guidewires or laser fibers, are most often of little consequence.
- Larger perforations often require premature termination of the procedure and in rare circumstances necessitate further surgical repair.

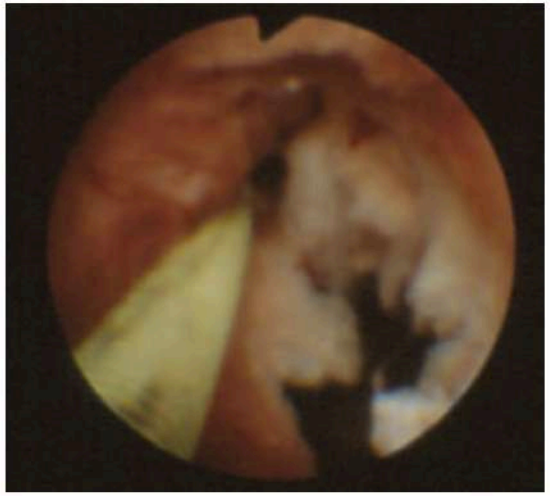

Figure 36-8 The ureteral wall is perforated (on the right side), while a guidewire is inserted into the ureteral lumen (on the left side).

Ureteral Perforation
How to Avoid?

- ✓ when a ureteral perforation is detected ureteral stent placement and antibiotics are advised.
- ✓ Duration of stenting can be as short as 1 week for small perforations to closer to 6 weeks for larger perforations.
- ✓ Careful technique, and never advancing the ureteroscope with accessories protruding from the end can minimize ureteral perforation.

Ureteral Intussusception

- Occurs when the ureteral mucosa circumferentially tears away from the underlying submucosa and then invaginates as a sleeve along the intact ureteral lumen.
- Associated with stone manipulation, retrograde pyelography, and during diagnostic endoscopic management of urothelial cell carcinoma.
- Retrograde pyelogram may show a "bell-shaped" ureter.
- If not found intraoperatively, it can present as ureteral obstruction at a later time.

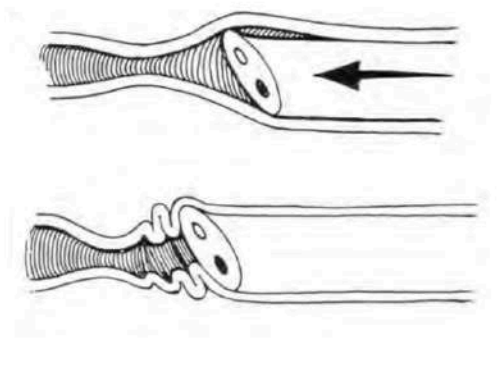

Figure 28-3 "Concertina" effect of the ureter that can result if the ureteroscope is advanced through a narrow segment of ureter without taking measures to maximize ureteral width. Ureteral perforation and even avulsion can result under such circumstances.

Ureteral Intussusception

- If possible, a ureteral stent should be placed once the injury is identified.
- If retrograde stenting is unsuccessful, then percutaneous nephrostomy tube placement is advised.
- ✓ These are only temporizing measures to drain the kidney, as the intussuscepted segment can be expected to fibrose and stricture off rather than heal with any meaningful lumen.
- ✓ Ultimately, resection of the intussuscepted nonviable segment is required with ureteroneocystotomy, ureteroureterostomy, ureteropyelostomy, ureteral substitution depending on the location and length of intussuscepted ureter.

Ureteral Avulsion

- Arguably the most severe intraoperative complication of ureteroscopy is ureteral avulsion.
- This occurs when the ureter circumferentially tears apart resulting in total discontinuity of the ureter.
- Immediate operative intervention to rectify the avulsion is usually the rule if recognized intraoperatively.
- Post-ureteroscopic reconstruction of the avulsed ureter can be quite challenging and may ultimately lead to loss of the affected kidney.

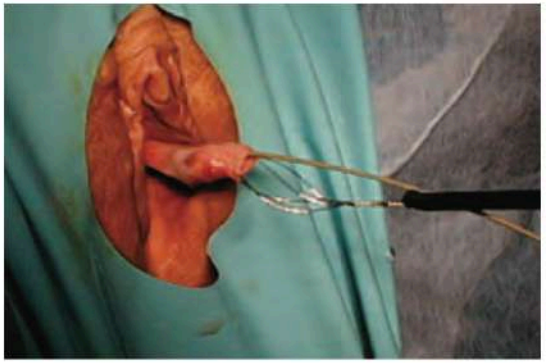

Figure 36-10 Ureteral avulsion: an impacted stone is entrapped into a basket. A long tract of ureter comes out of the external urethral meatus. A guidewire is still in the renal cavities.

Ureteral Avulsion

- The most common cause of avulsion is attempted basket extraction of stones or stone fragments too large to safely pass down the ureter.
- Other risk factors include stone basketing in the proximal ureter, retrieval of impacted stones, ureteral anatomic anomalies, and diseased ureters.
- Many of the early reports of ureteral avulsion from the 1980s and 1990s occurred in the setting of blind stone basket extraction, and in particular with the Dormia stone basket.

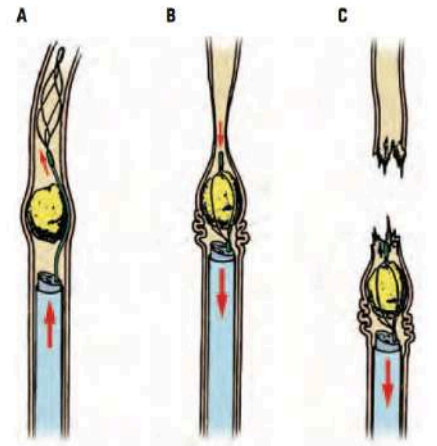

Figure 36-9 *A*, Antegrade passage of helical stone basket. Stone engaged and retrograde extraction attempted. *B*, Note proximal thinning of ureteral wall (*small arrow*) prior to avulsion. *C*, Complete avulsion (when excessive force is used).

Ureteral Avulsion

- The ureteropelvic junction was the most frequent site of avulsion and can be explained by the local anatomy.
- The ureteral muscular wall and urothelium is the thinnest at the ureteropelvic junction and proximal ureter.
- Additionally, the renal pelvis is relatively fixed compared to the rest of the ureter which has considerable mobility within the retroperitoneum.

Ureteral Avulsion
How to Avoid

- ✓ Avoid blind basketing of stones
- ✓ Use 0-tip niliton basket
- ✓ Use alternative approach for tricky, impacted proximal ureteric stones e.g. antegrade tripsy, laser tripsy insitu

Pain and renal colic

- The occurrence of pain in the postoperative period is inconsistently documented.
- Several studies in which patients with >2 cm stones were treated have reported a 13–15% incidence of renal colic or pain following intervention.
- Might be caused by clots, localized edema or ureteral spasms.
- Need administration of painkillers and parenteral fluids.
- In the incidence of persisting symptoms, it would be preferable to investigate the site and the extent of obstruction by means of an X-ray examination.

Ureteral stent related complications

- 50% of patients experienced discomfort secondary to ureteral stents with readmission up to 0.9% patients after URS.
- Stent migration occurs in up to 4.2% of patients and should be considered in any patient who presents to the emergency department with increasing pain or bladder symptoms.
- Stent encrustation occurs most commonly in patients lost to follow-up, with severe hypercalciuria, cystinuria, or in pregnant women due to hyper ltration hypercalciuria.

Ureteral stent related complications

- Apply a strict institutional protocol to ensure that stents have been removed to avoid the occurrence of "forgotten stent syndrome"
- Antimuscarinic alone or in combination with alpha-blockers has also been found to reduce the symptoms associated with stents.
- RCTs and meta-analysis have shown that ureteral double J stents are not indicated for uncomplicated URS.

Steinstrasse

- Steinstrasse, which is German for "street of stones," is a well-described complication after stone lithotripsy where a column of obstructing stone fragments accumulates within the ureter.

- This was originally described after SWL, but can also occur after ureteroscopy.
- Frequent stent placement after ureteroscopy may postpone the clinical presentation of steinstrasse until after ureteral stent removal.
- Fragment accumulation can lead to ureteral wall edema with subsequent luminal narrowing and further impede spontaneous passage.

Steinstrasse
How to avoid?

- ✓ For clinically symptomatic or persistent steinstrasse, a number of management
- ✓ percutaneous nephrostomy tube placement,
- ✓ ureteroscopy,
- ✓ and in very rare circumstance laparoscopic
- ✓ or open stone removal.

Infection and Fever

- UTI after ureteroscopy can range from routine and uncomplicated to life-threatening sepsis.
- The presence of calculi in the urinary tract can serve as a nidus for infection.
- Despite appropriate preoperative antibiotics and a negative urine culture, urinary calculi can still harbor bacteria that may cause serious infection during lithotripsy.
- The placement of ureteroscopes and instruments across the urethral meatus or skin can introduce bacteria into an otherwise sterile urinary tract.
- Pressurized irrigation can facilitate pyelovenous and pyelosinus translocation of uropathogens and promote sepsis.

Infection and Fever
How to Avoid?

- ✓ Sterilizing the urine with culture-directed antibiotics prior to ureteroscopy should be considered a must.
- ✓ Peri-ureteroscopic antibiotics for up to 24 h are recommended by the AUA.
- ✓ Using low pressure irrigation and only as much irrigation as necessary for adequate visualization can help minimize pyelovenous and pyelosinus backflow.
- ✓ continuous or intermittent bladder drainage can help reduce renal collecting system pressures subsequent microbia

Silent Hydronephrosis

- Incidence 2–5%.
- The concern in these patients is ongoing silent obstruction that may eventually lead to loss of the affected renal unit.
- Routine postoperative imaging may capture these patients at a time when intervention would be useful.
- Imaging in these studies was via many different modalities including computed tomography, intravenous pyelogram, renographyrenal ultrasound.

Silent Hydronephrosis

- Routine imaging may be more useful after complicated ureteroscopy, such as cases with impacted stones, postoperative pain, intraoperative ureteral injury, or when ureteral balloon-dilation was necessary.

- Renal ultrasound 4–6 weeks after complicated ureteroscopy is a good screening test and poses no known risks to patients.
- If hydronephrosis is detected, further function imaging studies and diagnostic studies can be considered.

Ureteral strictures

- 0–4% after ureteroscopy.
- A consequence of previous impacted stone, ureteral perforation, treatment of ureteric tumor
- Generally a silent phenomenon, so, a scan 3 months after URS has been suggested.
- Generally nonischemic and not very long, therefore, either dilation or laser endoureterotomy could be considered.
- Longer strictures or reoccurring strictures or those complicated by periureteral fibrosis will need open surgery.

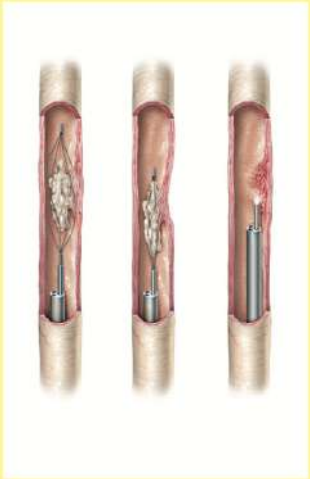

How to minimize complications related to URS?

- An update of the ICUD-SIU consultation on stone technology behind ureteroscopy has bee recently published, it highlights preoperative considerations, surgical technical considerations, and issues related to instrumentations and accessories.

- ***Cloutier and Traxer*** *World J Urol (2017)*

Preoperative considerations

- A complete history and physical examination evaluates if patient is known for any anatomic variations or malignant disease that may complicate URS.
- Complete blood count, basic metabolic panel, serum creatinine, and coagulation status.
- If possible, discontinuation of anticoagulation is recommended.
- Urinary culture before stone removal, and bacteriuria or UTI should be treated.
- Plain X-ray or CT scan of KUB is mandatory before any treatment.
- All patients should receive antibiotic prophylaxis

Operative considerations

- Some groups have described an advantage in which the ipsilateral leg was slightly extended or using Trendelenburg for ureteral stone treated with semi-rigid ureteroscope.
- Complete Cytourethroscopy.
- URS without the use of a safety guidewires is generally not recommended.
- In case of difficult access, JJ stent left in place and delayed URS after at least 7 d is safest alternative.

The patient is placed in a dorsal lithotomy position and all pressure points are padded. If possible, arrange the legs in position before anaesthesia induction, to give the patient the opportunity to voice any discomfort. Raising the contralateral leg might provide more room for manoeuvring a ureteroscope if necessary.

The Golden Rule

Never Pull Hard!